



**PRESENTING CLINICAL SIGNS**

**DATE** History: Grade IV/VI left-sided murmur. Radiographs show cardiomegaly. Gagging but not coughing.

4/25/23

**ECHOCARDIOGRAPHIC FINDINGS**

2D, M-mode, and Doppler study.

**PERFORMED BY:**

Dr. Meredith Swart

There is mild to moderate left atrial dilation. The mitral valve leaflets are thickened and exhibit systolic prolapse. There is Doppler evidence of mitral regurgitation present. There is mild to moderate left ventricular dilation. Left ventricular systolic function is hyperdynamic. The aorta and aortic valve are normal. Right atrial and right ventricular dimensions are normal. The tricuspid valve is normal. The pulmonary artery and pulmonic valve are normal. No shunting lesions are visualized. No pericardial effusion or cardiac masses are seen.

**INTERPRETED BY**

Keith Blass, DVM,  
MS, DACVIM  
(Cardiology)

LA - 28.8 mm  
LVIDd - 27.7 mm  
LVIDs - 13.4 mm  
FS - 51.6%  
LVOT - 0.96 m/s  
RVOT - 0.83 m/s

**PATIENT**

Grace Tobin

**ASSESSMENT/RECOMMENDATIONS**

Degenerative mitral valve disease

**SPECIES**

Canine

This examination demonstrates regurgitation of blood across Grace's mitral valve resulting from degenerative valve disease. Secondary to her regurgitation, Grace has mild to moderate dilation of both her left atrium and left ventricle, though her left ventricular systolic function is well-preserved. Grace's mitral valve disease does put her at risk for the development of a cough, though it's unlikely that her gag is cardiogenic in origin. Her cardiac disease also puts Grace at risk for exercise intolerance, syncope, and labored breathing, therefore, careful monitoring for the development of these clinical signs is recommended.

**BREED**

Dachshund

**SEX**

I recommend starting Grace on pimobendan (0.625 mg BID), as this medication should help to slow the progression of her mitral valve disease.

**FS**

A recheck echocardiogram is recommended in 9 months. Recheck radiographs are recommended if Grace experiences new respiratory clinical signs.

**AGE**

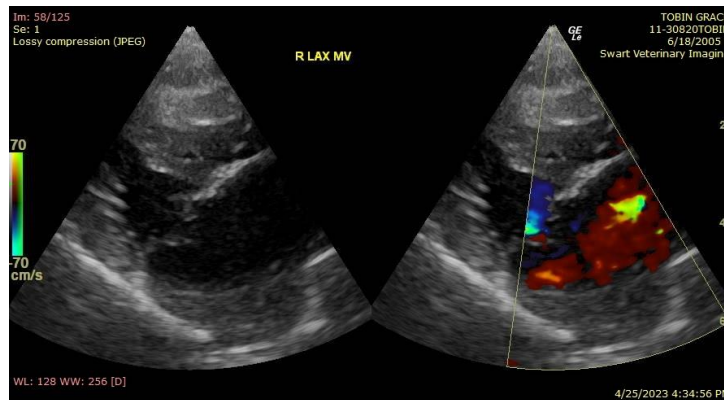
17 y

**WEIGHT**

6 lb

**HOSPITAL NAME**

Swart Veterinary  
Imaging



**REFERRING VET**

Dr. Swart



**DATE**

4/25/23

The information and recommendations provided are based on the images presented by the referring veterinarian. No evaluation can be communicated regarding pathology that was not visible in the image/video clips provided.

Thank you for this referral. If the clinical or image interpretation does not parallel your findings or if I can be of any further assistance please contact me.

**PERFORMED BY:**

Dr. Meredith Swart

**Keith Blass, DVM, MS, DACVIM (Cardiology)**  
KeithBlass@gmail.com  
631-804-5754

**INTERPRETED BY**

Keith Blass, DVM,  
MS, DACVIM  
(Cardiology)

**PATIENT**

Grace Tobin

**SPECIES**

Canine

**BREED**

Dachshund

**SEX**

FS

**AGE**

17 y

**WEIGHT**

6 lb

**HOSPITAL NAME**

Swart Veterinary  
Imaging

**REFERRING VET**

Dr. Swart